Early Outcomes from a Prospective Trial of Upright Image-Guided Proton Therapy for Locally Recurrent Head and Neck and Brain Malignancies

Philip Blumenfeld[1], Alexander Pryanichnikov[2,3], Yair Hillman[1], Ella Wajnryt[1], Aviad Berger[1], Shimshon Winograd[4], Eduard Arbit[1], Marc Wygoda[1], Ayman Salhab[1], Marcel Fang[1], Jon Feldman[1], Aron Popovtzer[1]

[1] Sharett Institute of Oncology, Hadassah Medical Center, Hebrew University of Jerusalem, Jerusalem, Israel.

[2] Institute of Biomedical Engineering (IBT), Karlsruhe Institute of Technology (KIT), Karlsruhe, Germany

[3] Division of Biomedical Physics in Radiation Oncology, German Cancer Research Center (DKFZ), Heidelberg, Germany.

[4] P-Cure Ltd./Inc., Shilat, Israel.

Abstract

Background and aims: Building on the 10-patient upright patient-positioning study [1] and the 20-patient interim clinical analysis [2], we present updated data on the feasibility, safety, and early disease control outcomes for 46 trial participants with recurrent, previously irradiated head and neck (H&N) or brain malignancies. These participants were treated with upright image-guided proton therapy (IGPT) and were followed up for up to 24 months.

Methods and results: Adult patients were treated prospectively at a single institution using IGPT facility equipped with scanning pencil-beam, six-degree-of-freedom robotic positioning, integrated vertical CT, and daily volumetric image guidance. Three-month response and local control were assessed by follow-up imaging; serious adverse events (SAEs) were reviewed descriptively. The cohort comprised 34 H&N and 12 brain patients as detailed in Table 1. At 3 months, 18 patients had complete response, 6 partial response, 10 stable disease, and 2 progressive disease; 7 died before assessment, 1 withdrew, and 2 were pending. Local control was 93.9% (31/33) among evaluable patients: 95.8% (23/24) for H&N and 88.9% (8/9) for brain malignancies. SAEs were documented in 18 patients (10 expected, 7 unexpected, 1 unclassified). Longitudinal treatment responses up to 24 months are shown in Figure 1.

Discussion and conclusions: This study update confirms the feasibility of upright IGPT and extends the encouraging early local-control findings of the interim clinical analysis. Longer follow-up is required to determine durability, late toxicity, and survival.

Keywords: Prospective Clinical Trial; Upright Proton Therapy.



Table 1. Patient data: disease, treatment characteristics and outcomes

Characteristic	Summary statistics
Histology	**Head and neck (n=34):** squamous cell carcinoma 13 (38.2%); nasopharyngeal carcinoma 3 (8.8%); tongue carcinoma 3 (8.8%); buccal mucosa cancer 2 (5.9%); maxillary sinus carcinoma 2 (5.9%); tonsillar carcinoma 2 (5.9%); sinonasal carcinoma arising in inverted papilloma 1 (2.9%); salivary gland carcinoma 1 (2.9%); hypopharyngeal carcinoma 1 (2.9%); cutaneous carcinoma involving the parotid 1 (2.9%); nasal cavity carcinoma 1 (2.9%); adenosquamous carcinoma of the palate 1 (2.9%); carcinoma ex pleomorphic adenoma of the parotid 1 (2.9%); posterior pharyngeal wall carcinoma 1 (2.9%); and ethmoid sinus carcinoma 1 (2.9%). **Brain (n=12):** glioblastoma 7 (58.3%), astrocytoma 4 (33.3%), oligodendroglioma 1 (8.3%)
Demographics	Age: median 62 years (range, 37-88); Male: 29 (63.0%); Female: 17 (37.0%)
Stage	III: 2 (4.3%); IV/IVA-IVC: 44 (95.7%)
Treatment	Dose: median 60 Gy (range, 18-72); Fractions: median 30 (range, 9-41)
3-month response (n=36)	CR: 18 (50.0%); PR: 6 (16.7%); SD: 10 (27.8%); PD: 2 (5.6%)
3-month local control	Overall: 31/33 (93.9%); Head and neck: 23/24 (95.8%); Brain: 8/9 (88.9%)
Patients with recorded SAEs	18/46 (39.1%); expected: 10; unexpected: 7; unclassified: 1

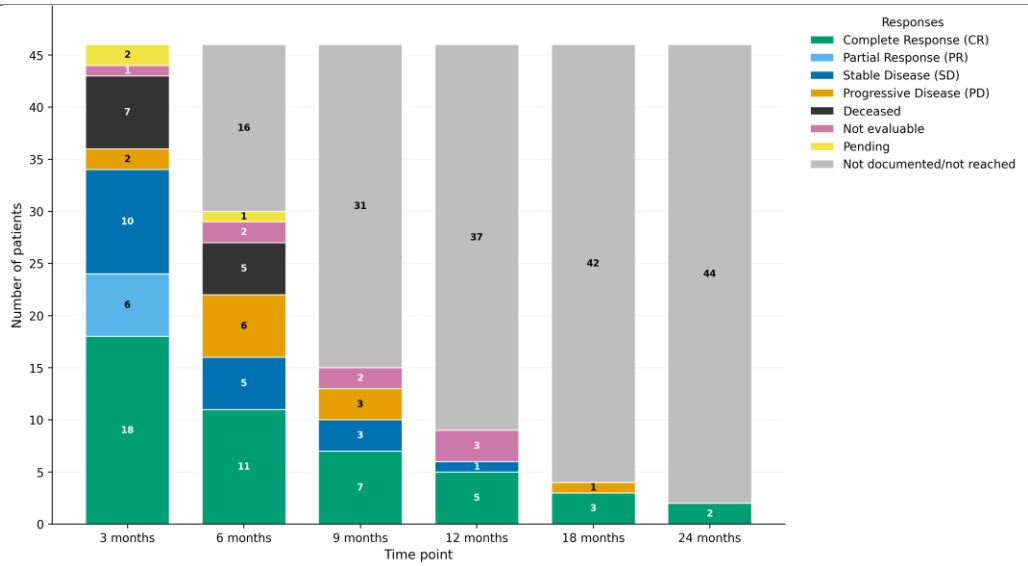

Figure 1. Longitudinal treatment response after upright IGPT.

References

1. Feldman J, Pryanichnikov A, Shwartz D, Hillman Y, Wygoda M, Blumenfeld P, Marash M, Popovtzer A. Study of upright patient positioning reproducibility in image-guided proton therapy for head and neck cancers. Radiother Oncol. 2024. 201:110572. doi: 10.1016/j.radonc.2024.110572.
2. Blumenfeld P, Pryanichnikov A, Hillman Y, Wajnryt E, Berger A, Winograd S, Wygoda M, Salhab A, Fang M, Feldman J, Popovtzer A. Prospective clinical trial of upright image-guided proton therapy for locally recurrent head and neck and brain malignancies. Radiother Oncol. 2025. 211:111097. doi: 10.1016/j.radonc.2025.111097.

