Early Clinical Experience of Upright Image-Guided Proton Therapy for Pediatric CNS Malignancies

Philip Blumenfeld[1], Alexander Pryanichnikov[2,3], Zelig Tochner[4], Marcel Fang[1], Ayman Salhab[1], Marc Wygoda[1], Yair Hillman[1], Eduard Arbit[1], Ella Wajnryt[1], Aviad Berger[1], Shimshon Winograd[5], Gal Goldstein[6], Iris Fried[7], Efrat Landau[8], Jon Feldman[1], Aron Popovtzer[1]

[1] Sharett Institute of Oncology, Hadassah Medical Center, Hebrew University of Jerusalem, Jerusalem, Israel.
[2] Institute of Biomedical Engineering (IBT), Karlsruhe Institute of Technology (KIT), Karlsruhe, Germany
[3] Division of Biomedical Physics in Radiation Oncology, German Cancer Research Center (DKFZ), Heidelberg, Germany.
[4] Department of Radiation Oncology, Hospital of the University of Pennsylvania, Philadelphia, Pennsylvania, USA.
[5] P-Cure Ltd./Inc., Shilat, Israel.
[6] The Dyna and Fala Weinstock Department of Pediatric Hematology-Oncology, Hadassah Medical Center, Hebrew University of Jerusalem, Jerusalem, Israel.
[7] Pediatric Palliative Care Unit, Shaare Zedek Medical Center, Jerusalem, Israel.
[8] Department of Radiation Oncology, Sheba Medical Center, Tel Hashomer, Israel.

Abstract

Purpose: To report positioning accuracy, dosimetric metrics and early clinical outcomes of upright image-guided proton therapy (IGPT) in pediatric CNS tumors treated on a gantry-less system.

Methods: Ten patients (median age 7 years, range 2-11; 8 male) with CNS tumors were treated between July 2025 and June 2026. Indications were craniospinal irradiation in five and brain-only treatment in five. Diagnoses included craniopharyngioma (n=3), medulloblastoma (n=3), CNS neuroblastoma (n=2), high-grade neuroepithelial tumor (n=1), and meningeal rhabdomyosarcoma (n=1). Treatments used robotic six-degree-of-freedom upright positioning, vertical CT guidance, daily 3D/3D image registration, field-specific 2D/3D verification and proton pencil beam delivery. Some patients were treated with monitored anesthesia care, while others were not.

Results: All patients completed treatment at data cutoff. Mean 3D/3D translational corrections were $\langle \Delta x_{3D/3D} \rangle$=-0.4±4.9 mm, $\langle \Delta y_{3D/3D} \rangle$=-0.7±3.4 mm, $\langle \Delta z_{3D/3D} \rangle$=-1.6±3.5 mm and rotational - $\langle \Delta \phi_{x3D/3D} \rangle$=-0.2±1.8°, $\langle \Delta \phi_{y3D/3D} \rangle$=0.0±2.0° and $\langle \Delta \phi_{z3D/3D} \rangle$=0.0±1.5°; 2D/3D translational corrections $\langle \Delta x_{2D/3D} \rangle$=-0.0±4.6 mm, $\langle \Delta y_{2D/3D} \rangle$=-2.6±3.1 mm, $\langle \Delta z_{2D/3D} \rangle$=0.6±4.0 mm and rotational - $\langle \Delta \phi_{x2D/3D} \rangle$=-0.1±1.8°, $\langle \Delta \phi_{y2D/3D} \rangle$=0.0±1.8° and $\langle \Delta \phi_{z2D/3D} \rangle$=0.2±1.6°. Key dosimetric indexes for organ at risks are presented in table 1. At three months, local control was observed in all seven evaluable patients: complete response in three, partial response in one, and stable disease in three. No serious adverse events were recorded in the available dataset.

Conclusion: Upright IGPT was feasible for pediatric CNS treatment, providing reproducible positioning, clinically acceptable dosimetry, and encouraging early disease control. Prospective follow-up is warranted.

Keywords: Prospective Clinical Trial; Upright Proton Therapy.



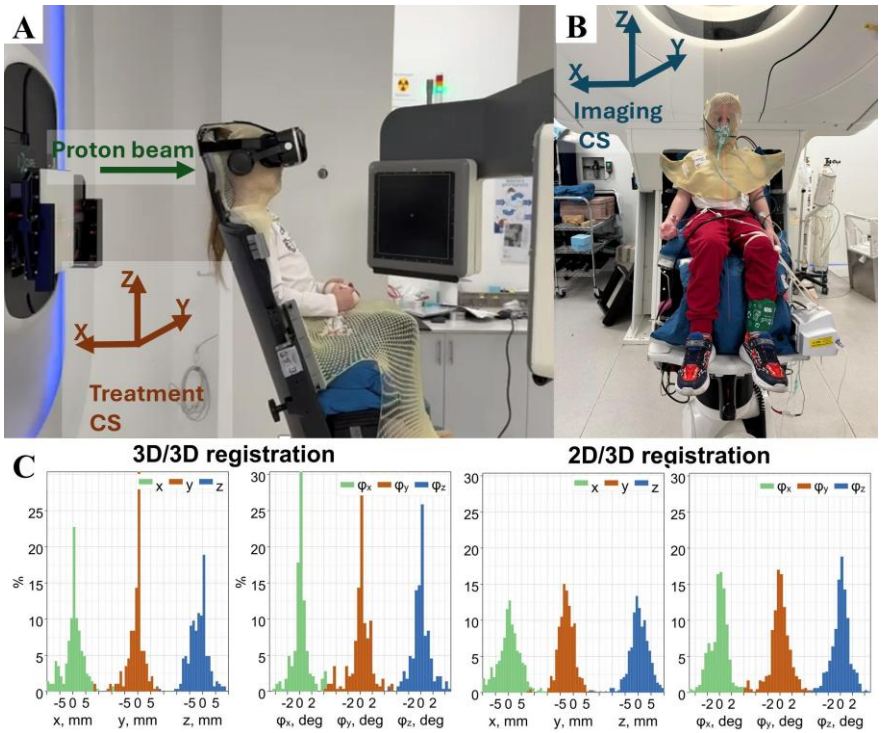

Figure 1. Pediatric Patient Positioning and Immobilization for Upright Proton Therapy: (A) CSI patient without anesthesia; (B) patient without anesthesia; (C) positioning accuracy distribution for daily setup (3D/3D) and each field irradiation (2D/2D).

Table 1. Selected OAR dose metrics for the clinical upright IGPT plans (Gy_{RBE}).

Metric	Metric	#1	#2	#3	#4	#5	#6	#7	#8	#9	#10
Prescription	D, Gy_{RBE}	30.6	54	52.2	54	54	54	54	60	50.4	54
Brainstem	D_{max}, Gy_{RBE}	18.9	40.2	55.8	NA*	48.4	37.8	22.1	0.0	44.2	41.6
Spinal cord	D_{max}, Gy_{RBE}	NA*	0.0	NA*	NA*	NA*	38.2	NA*	NA*	29.7	NA*
Optic chiasm	D_{max}, Gy_{RBE}	18.9	54.8	53.8	NA*	52.6	37.6	21.7	0.0	32.5	41.7
Optic nerve L	D_{max}, Gy_{RBE}	18.9	54.5	52.6	NA*	43.1	37.6	21.7	0.0	6.8	42.0
Optic nerve R	D_{max}, Gy_{RBE}	22.6	54.8	53.5	NA*	45.7	37.7	21.5	0.1	37.2	41.8
Lens L	D_{max}, Gy_{RBE}	1.5	0.0	0.0	13.0	0.0	NA*	NA*	NA*	0.1	NA*
Lens R	D_{max}, Gy_{RBE}	1.9	0.0	0.1	15.8	0.0	NA*	NA*	NA*	1.4	NA*
Cochlea L	D_{mean}, Gy_{RBE}	13.7	NA*	NA*	23.5	0.2	36.7	0.1	NA*	1.6	40.8
Cochlea R	D_{mean}, Gy_{RBE}	13.2	NA*	NA*	22.9	0.2	36.2	15.9	0.0	NA*	41.0

* Indicates structure not contoured/applicable in that plan.

References

1. Blumenfeld P, Pryanichnikov A, Tochner Z et al. Pediatric CNS relapse of neuroblastoma treated with upright proton craniospinal irradiation. Clin Transl Radiat Oncol. 2025; 56:101080. doi: 10.1016/j.ctro.2025.101080.

