First Pelvic Irradiation Using Upright Image-Guided Proton Therapy

Philip Blumenfeld[1], Alexander Pryanichnikov[2,3], Yair Hillman[1], Ella Wajnryt[1], Aviad Berger[1], Shimshon Winograd[4], Eduard Arbit[1], Marc Wygoda[1], Ayman Salhab[1], Marcel Fang[1], Jon Feldman[1], Aron Popovtzer[1]

[1] Sharett Institute of Oncology, Hadassah Medical Center, Hebrew University of Jerusalem, Jerusalem, Israel.

[2] Institute of Biomedical Engineering (IBT), Karlsruhe Institute of Technology (KIT), Karlsruhe, Germany

[3] Division of Biomedical Physics in Radiation Oncology, German Cancer Research Center (DKFZ), Heidelberg, Germany.

[4] P-Cure Ltd./Inc., Shilat, Israel.

Abstract

Background and aims: Upright image-guided proton therapy (IGPT) is an emerging treatment modality, with an increasing number of centers in the USA and worldwide. The integration of vertical CT enables diagnostic imaging, treatment simulation, and treatment delivery in the same patient position. However, experience remains limited mainly to sites, including head and neck [1,2], CNS [3], and lung tumors [4]. Demonstrating safe and accurate treatment of lower anatomical targets is an important step toward establishing upright IGPT as a universal treatment approach. Here, we report the first pelvic-region irradiation performed with upright IGPT.

Methods and results: A 36-year-old male patient with pelvic Ewing sarcoma was treated using a pencil-beam scanning, six-degree-of-freedom robotic positioning, integrated vertical CT, and daily volumetric image guidance. The prescribed dose was 57.2 Gy_{RBE} in 26 fractions. Upright positioning was well tolerated. Mean daily CT-based translational corrections were $\langle \Delta x_{3D/3D} \rangle$=1.8±2.0 mm, $\langle \Delta y_{3D/3D} \rangle$=-0.2±2.8 mm, $\langle \Delta z_{3D/3D} \rangle$=-1.1±2.8 mm; rotational corrections were $\langle \Delta \phi_{x3D/3D} \rangle$=-0.2±1.6°, $\langle \Delta \phi_{y3D/3D} \rangle$=0.4±0.5° and $\langle \Delta \phi_{z3D/3D} \rangle$=0.4±0.5°. Pre-field X-ray-based corrections were $\langle \Delta x_{2D/3D} \rangle$=1.9±2.0 mm, $\langle \Delta y_{2D/3D} \rangle$=0.2±5.1 mm, $\langle \Delta z_{2D/3D} \rangle$=0.9±1.5 mm; rotations were $\langle \Delta \phi_{x2D/3D} \rangle$=0.1±1.7°, $\langle \Delta \phi_{y2D/3D} \rangle$=0.3±0.5° and $\langle \Delta \phi_{z2D/3D} \rangle$=0.5±0.7°. All fractions were completed without interruption.

Discussion and conclusions: This first pelvic upright IGPT case confirms the feasibility of accurate volumetric image-guided proton irradiation in the upright position within a clinical treatment workflow. Its importance lies in extending upright IGPT beyond upper-body indications, supporting its potential clinical role as a site-independent therapy platform. Longer follow-up is required to assess toxicity, durability of local control, and survival.

Keywords: Prospective Clinical Trial; Upright Proton Therapy.



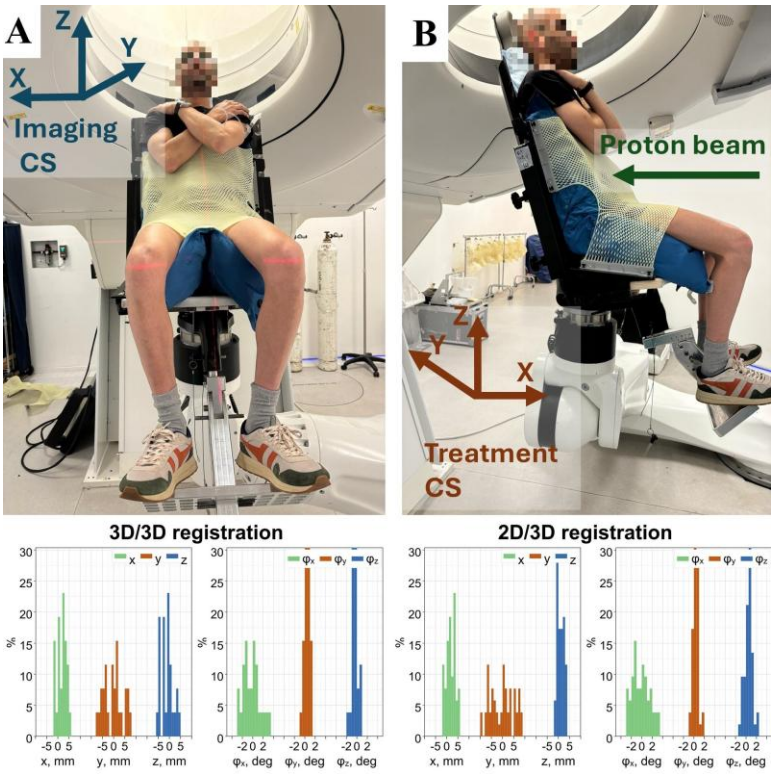

Figure 1. Patient setup and daily CT-based and pre-field X-ray-based corrections.

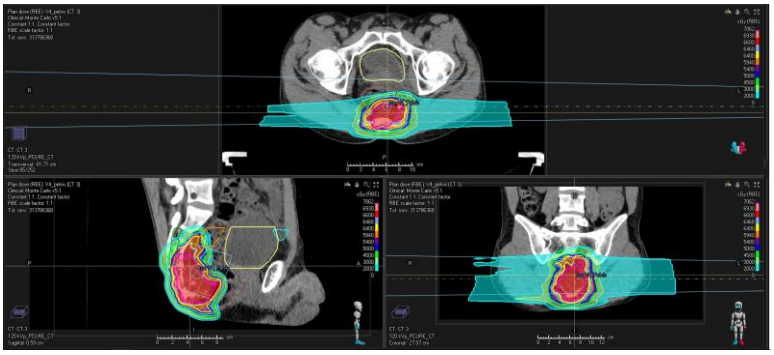

Figure 2. Dose distribution for upright IGPT pelvic irradiation.

References

1. Feldman J, Pryanichnikov A, Shwartz D et al. Study of upright patient positioning reproducibility in image-guided proton therapy for head and neck cancers. Radiother Oncol. 2024. 201:110572. doi: 10.1016/j.radonc.2024.110572.
2. Blumenfeld P, Pryanichnikov A, Hillman Y et al. Prospective clinical trial of upright image-guided proton therapy for locally recurrent head and neck and brain malignancies. Radiother Oncol. 2025. 211:111097. doi: 10.1016/j.radonc.2025.111097.
3. Blumenfeld P, Pryanichnikov A, Tochner Z et al. Pediatric CNS relapse of neuroblastoma treated with upright proton craniospinal irradiation. Clin Transl Radiat Oncol. 2025; 56:101080. doi: 10.1016/j.ctro.2025.101080.
4. Marano J, Kissick MW, Underwood TSA et al. Relative thoracic changes from supine to upright patient position: A proton collaborative group study. J Appl Clin Med Phys. 2023; 24(12):e14129. doi: 10.1002/acm2.14129.

